

Unleashing the Furry Beast: Exploring the Fascinating World of Hypertrichosis Lanuginosa

Dipankar Maiti¹, Rose Mary George²

¹ PG Scholar, NDRK College of Nursing, Rajiv Gandhi University of Health Sciences, Bangalore, Karnataka, India.²Professor, Parul Institute of Nursing, Parul University, Vadodara, Gujarat

How to cite this article: Maiti D, George RM. Unleashing the Furry Beast: Exploring the Fascinating World of Hypertrichosis Lanuginosa. 2023;11(2):10-16.

ABSTRACT

Hypertrichosis lanuginosa is a rare medical condition characterized by the excessive growth of fine, soft, and unpigmented hairs all over the body, particularly in the forehead, cheeks, ears, and nose. It can be either congenital or acquired, with the acquired type being more commonly associated with underlying malignancy. Congenital hypertrichosis lanuginosa is a genetic disorder that is inherited in an autosomal dominant manner, with some cases exhibiting spontaneous mutations. The condition manifests as an overproduction of lanugo hairs, the fine and unpigmented hair that covers the body of a fetus. This type of hypertrichosis often leads to difficulties in daily life and can cause emotional distress due to its unusual appearance. Acquired hypertrichosis lanuginosa, on the other hand, often occurs in adults and is frequently associated with malignancy, particularly adenocarcinomas. The exact mechanism of hypertrichosis lanuginosa is not yet fully understood, but it is believed to be due to the secretion of growth factors or hormones from cancer cells, which can stimulate the hair follicles to produce excessive amounts of hair. The diagnosis of hypertrichosis lanuginosa is mainly clinical, and a thorough physical examination is required. In cases where an underlying malignancy is suspected, further tests such as blood tests, imaging studies, and biopsy may be necessary. Treatment options for hypertrichosis lanuginosa are limited, and there is no definitive cure for the condition. Hair removal procedures such as laser therapy, electrolysis, and depilatory creams can provide temporary relief, but the hair usually grows back after some time. In cases of underlying malignancy, the treatment of the cancer may lead to the resolution of hypertrichosis lanuginosa. Overall, hypertrichosis lanuginosa is a rare medical condition that can occur either congenitally or acquired, and it is often associated with malignancy. The diagnosis of hypertrichosis lanuginosa can be challenging, and further testing may be required to identify any underlying malignancy. Although treatment options are limited, hair removal procedures and treating the underlying malignancy may provide temporary relief. Further research is needed to fully understand the underlying mechanisms of hypertrichosis lanuginosa and develop more effective treatment options.

Keywords: Acquired hypertrichosis lanugo-type, hypertrichosis lanuginosa acquisita, malignancy, paraneoplastic.

INTRODUCTION

Lanugo hairs are typically present from the third month of fetal development until just before birth, and are almost completely shed by then. Acquired hypertrichosis lanuginosa


is an uncommon condition that causes rapid growth of long, fine, lanugo-like hair, mainly on the forehead, eyebrows, ears, and nose, during adulthood. This condition is similar to congenital hypertrichosis lanuginosa

Corresponding author: Dipankar Maiti, PG Scholar, NDRK College of Nursing, Rajiv Gandhi University of Health Sciences, Bangalore, Karnataka, India.

Email: dipankarmaiti2015@gmail.com

(see hypertrichosis), but it usually appears later in life and is commonly linked with an underlying cancer. Hypertrichosis is defined as excessive hair growth on any part of the body in either males or females. It's important to differentiate hypertrichosis from hirsutism, which is a term used to describe females who have excessive amounts of terminal hairs in androgen-dependent regions.¹

Hypertrichosis refers to the excessive growth of hair on any part of the body in both males and females. It's crucial to differentiate hypertrichosis from hirsutism, which is a term used exclusively for females who develop an excessive amount of terminal hair in androgen-dependent areas. There are various ways to categorize hypertrichosis, including distribution (generalized versus localized), age of onset (congenital versus acquired), and hair type (vellus versus terminal). Generalized hypertrichosis has several forms, such as congenital generalized hypertrichosis (further divided into congenital hypertrichosis lanuginosa, hypertrichosis universalis, and hypertrichosis universalis congenita), prepubertal hypertrichosis, acquired generalized hypertrichosis, and acquired hypertrichosis lanuginosa. Each of these types has distinct clinical features and causes. It is worth noting that the etiology and clinical findings vary for each form.^{2,3}



METHODOLOGY

This comprehensive review provides insightful information on Hypertrichosis Lanuginosa including updated details on possible treatments in all areas. The information was collected through a computerized search from various research articles and reputable websites.

BACKGROUND

Throughout history, there has been a notable fascination with the unusual and the unknown. In the past, people born with congenital disorders causing excessive body hair growth have been sensationalized and even romanticized to the point where those with rare hypertrichosis syndromes became popular attractions in 19th-century sideshow acts. One such individual, **Fedor Jeftichew**, also known as **Jojo the Dog-faced Boy**, gained notoriety after being exhibited by PT Barnum in the United States during the 1800s. These individuals were referred to by various names such as dog-men, hair-men, human Skye terriers, ape-men, werewolves, and Homo sylvestris. As far back as the Middle Ages, around 50 individuals with congenital hypertrichosis have been documented, with approximately 34 cases being adequately and definitively recorded in the literature.⁴

ETYMOLOGY

The term "hypertrichosis" derives from Greek roots (hyper-, meaning "excess"; trikhos, meaning "hair"; and -osis, meaning "formation"), and it refers to a medical condition characterized by excessive hair growth all over the body. In medieval times, people with this condition were not referred to using this term. Instead, they were often called "hairy men and women". Although they may have been mistaken for savages, who also have excessive hair, it's important to note that these two groups belong to different categories. Savages were associated with social or religious isolation and were deemed closer to animals than to humans due to their exceptional strength. In contrast, people with

hypertrichosis were not necessarily isolated and often lived in courts as entertainers, along with other “monster-like” subjects.⁵



HISTORY

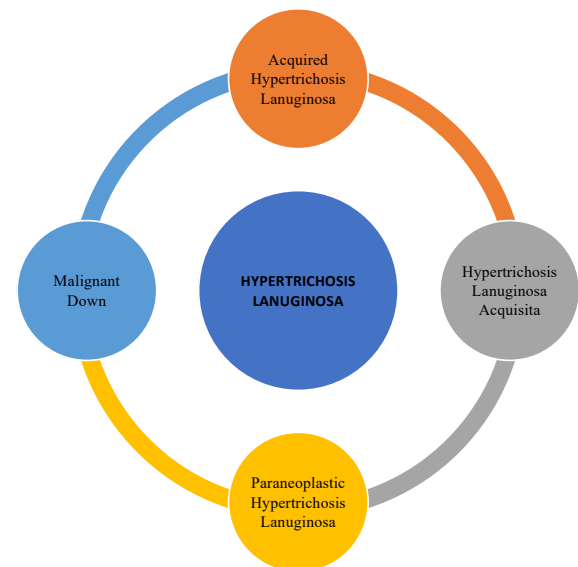
The first documented case of hypertrichosis was **Petrus Gonsalvus** from the Canary Islands, as noted by Ulisse Aldrovandi in his posthumous *Monstrorum Historia cum Paralipomenis historiae omnium animalium* in **1642**. Aldrovandi observed that Gonsalvus' family had a history of hypertrichosis, with two daughters, a son, and a grandchild also displaying excessive hair growth. This family became known as the Ambras family after the portraits of them found in Ambras Castle near Innsbruck. Over the next 300 years, approximately 50 cases of hypertrichosis were recorded. In 1873, Rudolf Virchow described a specific form of hypertrichosis that also caused gingival hyperplasia. In the summer of 2019, Spain's health ministry reported that 17 children had developed “werewolf syndrome” due to a medication error. Instead of receiving omeprazole for gastric reflux, the children were given minoxidil, a medication for hair loss. The laboratory responsible for the error, FarmaQuimica Sur in Malaga, has

been closed as a precaution, although the details of how the mistake occurred are not yet clear.⁵

DEFINITION

Hypertrichosis is a medical condition that is characterized by excessive hair growth on any part of the body, regardless of the individual's gender. It is crucial to differentiate hypertrichosis from hirsutism, which is a term used specifically for females who experience excessive growth of terminal hairs in androgen-dependent areas. This article discusses the appropriate situations in which hypertrichosis should be considered in the differential diagnosis, outlines the proper evaluation methods for diagnosing the condition, and emphasizes the importance of an interprofessional healthcare team in providing optimal care for patients with hypertrichosis.²

OTHER NAMES



TYPES

Congenital

- Hypertrichosis lanuginosa
- Generalized hypertrichosis
- Terminal hypertrichosis
- Circumscribed hypertrichosis
- Localized hypertrichosis
- Nevoid hypertrichosis

Acquired

- Hypertrichosis lanuginosa
- Generalized hypertrichosis
- Patterned hypertrichosis
- Localized hypertrichosis

CAUSES

Hypertrichosis lanuginosa acquisita is a disorder of unidentified cause, but it is supposed to be a response to hormones or substances released by tumors. Typically, cases of acquired hypertrichosis lanuginosa are associated with an internal malignancy, such as lung, breast, uterine, colorectal, lymphoma, or bladder cancer. In some cases, the hypertrichosis may appear up to 2 years prior to cancer diagnosis, and is often a late sign of cancer. Non-malignant diseases, such as malnutrition from anorexia nervosa, hyperthyroidism, and HIV/AIDS, may also be associated with acquired hypertrichosis lanuginosa. Additionally, certain drugs, such as ciclosporin, phenytoin, interferon, spironolactone, and corticosteroids, may cause acquired generalized hypertrichosis.

- Antibiotics such as streptomycin
- Diuretics (acetazolamide)
- Antiseptic agents (hexachlorobenzene)
- Chelators (penicillamine)
- Interferon-alpha
- NSAID drugs such as benoxaprofen and corticosteroids
- Anticonvulsants (phenytoin)
- Immunosuppressives (cyclosporine, mycophenolate mofetil)
- Psoralens (methoxypsoralen, trimethylpsoralen)
- Vasodilators (diazoxide, minoxidil, prostaglandin E1)
- Fenoterol
- EGFR inhibitors (cetuximab, panitumumab, erlotinib, gefitinib)⁶

PATHOPHYSIOLOGY

Hypertrichosis can occur due to several mechanisms. One of the causes is related to

the transition of vellus hair follicles to terminal hair follicles in certain areas of the skin. During puberty, vellus hair follicles in the groin and underarms mature into terminal hair follicles. However, in hypertrichosis, this switch occurs in areas that typically do not produce terminal hair. The exact process of this transformation is not fully understood. Another mechanism involves changes in the hair growth cycle, which consists of three stages: the anagen phase (hair growth), the catagen phase (hair follicle death), and the telogen phase (hair shedding). If the anagen phase is prolonged beyond the normal duration, excessive hair growth can occur in that area.⁸

CLINICAL FEATURES

Hypertrichosis lanuginosa acquisita is a medical condition characterized by the growth of fine, soft, and unpigmented hair all over the body except for the soles of the feet, palms of the hands, and mucous membranes. The growth of hair can occur rapidly, with significant changes noticeable within a few weeks to months. HLA is frequently linked with internal malignancies, especially breast, lung, and uterine cancers, with hypertrichosis often being the first indication of the tumour. HLA may also be associated with non-malignant ailments such as malnutrition, hyperthyroidism, and AIDS. The treatment of HLA includes dealing with the underlying condition, if present, and controlling excessive hair growth through techniques such as hair removal, topical hair inhibitors, or systemic medications.

DIFFERENTIAL DIAGNOSIS & PITFALLS

- **Hirsutism** - Hirsutism is a condition characterized by excessive hair growth in females, distributed in a male pattern. Unlike HLA, the hairs in hirsutism are thicker and are terminal in nature. Patients with hirsutism may also display physical characteristics indicative of virilization.
- **Hypertrichosis lanuginosa congenita** - The presence of an excessive number of

lanugo hairs is noticeable at or shortly after birth and does not resolve with age.

- **Acquired hypertrichosis** - This kind of hair growth is distinguished by the emergence of thick, coarse terminal hairs that occur as a result of medication use (such as cyclosporine, streptomycin, penicillin, phenytoin, spironolactone, diazoxide, minoxidil, interferon, and corticosteroids) or metabolic/endocrine disorders (including anorexia nervosa, HIV/AIDS, Cushing syndrome, and thyroid dysfunction).
- **Becker nevus** - A smooth muscle hamartoma, which is confined to a specific area, generally manifests as a sizable hyperpigmented patch with increased thick, terminal hairs on the upper extremities or trunk.

TREATMENT

There is no exact treatment for the disorder named acquired hypertrichosis lanuginosa. To advance the cosmetic advent the following hair exclusion techniques may be used:

- Eflornithine cream
- Laser hair removal
- Mechanical or chemical depilation

Treatment options for HLA depend on the underlying cause of the condition. For cases associated with internal malignancy, the mainstay of treatment is addressing the cancer through surgery, radiation therapy, and chemotherapy. In some cases, resolution of hypertrichosis may occur following treatment of the cancer. For cases associated with non-malignant causes, such as malnutrition, hyperthyroidism, or HIV, treating the underlying condition may lead to improvement or resolution of hypertrichosis. In cases where HLA is drug-induced, discontinuation or substitution of the offending medication may lead to resolution of the condition. There are limited reports of success with topical and systemic medications such as minoxidil, finasteride,

spironolactone, and eflornithine, but more research is needed to establish their efficacy in treating HLA.

COMPLICATIONS

There are several potential complications associated with Hypertrichosis lanuginosa acquisita. One of the most significant is the underlying malignancy that is often associated with the condition. This can lead to a range of complications, including metastasis and other cancer-related symptoms. In addition, the excessive hair growth itself can cause discomfort and affect quality of life, leading to social and psychological difficulties. Treating the underlying cancer may also involve aggressive interventions such as chemotherapy and radiation, which can have their own set of side effects and complications. Furthermore, certain medications used to treat the condition may also have potential side effects, such as immunosuppression, which can increase the risk of infection.

PROGNOSIS

The prognosis for individuals with hypertrichosis varies based on the type of hypertrichosis they have. Those with hypertrichosis associated with genetic syndromes typically experience lifelong symptoms. In contrast, drug-induced hypertrichosis is typically reversible once the medication is discontinued.

REPORTED RENOWNED CASES

FIRST REPORTED CASE-Petrus Gonsalvus, the first recorded case of hypertrichosis.⁵

Case No. 1: A mediastinal mass-related chest discomfort and electrocardiographic abnormalities led to the hospitalisation of a 66-year-old woman with a history of breast and endometrial cancer. An erythematous plaque on the right breast areola was seen during examination, and mammary Paget's disease was identified. A right breast infiltrating ductal carcinoma that had progressed to the anterior mediastinum was discovered during a

subsequent examination. Due to the patient's excessive eyebrow and eyelash growth as well as the fine, whitish lanugo hair on the cheeks, chin, nose, and ears, pleural effusion was treated, and a dermatologist's opinion was sought. Leukocytosis, low haemoglobin levels, and high g-glutamyltransferase and prolactin levels were all discovered through blood tests. Dehydroepiandrosterone, basal 17OH-progesterone, and estradiol levels were abnormally high.⁹

Case No. 2: A 66-year-old woman with adenoacanthoma of the uterus received JCo therapy to the pelvis followed by total abdominal hysterectomy and bilateral salpingoophorectomy. Metastatic adenoacanthoma was detected in the left cervical lymph node 2 months postoperatively, and 4 months later, she developed downy hair growth on her face and later on her body. The patient was referred to Wayne State University Oncology Service, where physical examination revealed cervical lymphadenopathy, a large retroperitoneal mass, and extensive fine, soft, white downy hair growth. Metabolic, hematologic, and endocrine studies were normal except for elevated LDH, alkaline phosphatase, and CEA levels. Roentgenograms, including bone survey and liver and brain scan were normal, except for a positive gallium scan in the left supraclavicular fossa. Skin biopsy from the shoulder showed thin, unmedullated hair, and a small avascular dermal papilla. The diagnosis was "malignant fuzz." The patient did not respond to hormonal therapy or multiple chemotherapeutic agents and died in November 1973. Autopsy permission was not granted.¹⁰

Case No. 3: Patient B. B. was a 35-year-old woman who was stated to the Wayne State University Oncology Service in the month of September 1973, due to superior vena cava obstacle. Prior to the onset of cervical lymph node enlargement, she had noticed the onset of new facial and shoulder hair growth a year ago. The physical examination revealed facial edema, jugular venous distention, and a

systolic murmur heard over the right second intercostal area radiating into the neck. Grayish-white lanugo hair was noted over the face and both shoulders, with a normal hair pattern over the trunk, arms, and legs. A superior mediastinal mass extending into the right hilar area was detected through a chest roentgenogram. The biopsy slides were reviewed and showed malignant lymphoma, diffuse histiocytic type. Extensive laboratory studies were normal, except for an elevated LDH. The patient was treated with 60Co therapy to the mediastinum and cervical area, which provided a dramatic relief of facial and cervical edema. However, subsequent celiotomy showed extensive mesenteric nodal involvement with lymphoma. In summary, Patient B. B. presented with superior vena cava obstruction and lymphoma, diffuse histiocytic type. The onset of new facial and shoulder hair growth a year prior to cervical lymph node enlargement was also noted. Despite the initial success of 60 Co therapy, the patient's subsequent celiotomy revealed extensive mesenteric nodal involvement with lymphoma.¹⁰

CONCLUSION

In conclusion, Hypertrichosis lanuginosa acquisita is a rare and poorly understood condition characterized by excessive growth of fine, unpigmented hair on the face, trunk, and extremities. It is most commonly associated with an underlying internal malignancy, with lung, breast, and uterine cancers being the most frequently reported. Early recognition of hypertrichosis lanuginosa acquisita and prompt investigation for an underlying malignancy is crucial. Although the condition can be cosmetically distressing, treatment of the underlying cancer is the most effective approach to manage the condition. Further research is needed to fully understand the pathophysiology of the condition and to improve diagnosis and management strategies. A collaborative, interdisciplinary approach is crucial to manage hypertrichosis lanuginosa acquisita and to optimize patient outcomes.

LIST OF ABBREVIATIONS

NSAID- Non-steroidal anti-inflammatory drugs

EGFR - Estimated glomerular filtration rate

HIV - Human immunodeficiency virus

AIDS - Acquired Immune Deficiency Syndrome

HLA - Hypertrichosis lanuginosa acquisita

LDH - lactate dehydrogenase

SOURCE OF FUNDING

Self(review article), No financial support was provided relevant to this article.

CONFLICT OF INTEREST- Have no conflict of interest relevant to this article

ETHICAL CLEARANCE- Not required.

REFERENCES

1. Knowling MA, Meakin JW, Hradsky NS, Pringle JF. Hypertrichosis lanuginosa acquisita associated with adenocarcinoma of the lung. *Can Med Assoc J* [Internet]. 1982 Jun 6 [cited 2023 May 30];126(11):1308.
2. Saleh D, Yarrarapu SNS, Cook C. Hypertrichosis. *Hair, Hair Growth and Hair Disorders* [Internet]. 2022 Jul 4 [cited 2023 Apr 11];333-56.
3. Hernandez MI, Castro A, Bacallao K, Avila A, Espinoza A, Trejo L, Iñiguez G, Codner E, Cassorla F. Hormonal profile and androgen receptor study in prepubertal girls with hypertrichosis. *Int J Pediatr Endocrinol.* 2014;2014(1):6. [PMC free article] [PubMed] Ggfgngh
4. Congenital Hypertrichosis Lanuginosa: Background, Pathophysiology, Etiology [Internet]. [cited 2023 Apr 11].
5. Taylor, Sarah K (June 18, 2009). "Congenital Hypertrichosis Lanuginosa". *Emedicine. Medscape.* Retrieved December 4, 2009.
6. Hypertrichosis lanuginosa acquisita | DermNet [Internet]. [cited 2023 Apr 11]. Available from: <https://dermnetnz.org/topics/acquired-hypertrichosis-lanuginosa>
7. Sindhuphak W, Vibhagool A. Acquired hypertrichosis lanuginosa. *Int J Dermatol* [Internet]. 1982 [cited 2023 May 30];21(10):599-601. Available from: <https://pubmed.ncbi.nlm.nih.gov/7160950/>
8. Hordinsky, Maria K.; Amy J. McMichael (2008). *Hair and Scalp Diseases: Medical, Surgical, and Cosmetic Treatments (Basic and Clinical Dermatology)*. Informa Healthcare. p. 221. ISBN 978-1-57444-822-1.
9. Sindhuphak W, Vibhagool A. Acquired Hypertrichosis Lanuginosa. *Int J Dermatol.* 1982;21(10):599-601.
10. Kassis V, Kassis E, Keiding L, Thomsen HK. Hypertrichosis lanuginosa acquisita associated with multiple malignancies. *J Am Acad Dermatol.* 1985;12(6):1106-7.