

Case Report - Anesthetic Challenges of Congenital Diaphragmatic Hernia Repair in an Adult

Smriti Sinha¹, Varghese Zachariah K²

¹Assistant Professor, Department of Anesthesiology and Critical Care, Srinivas Institute of Medical Sciences, Mukka, Mangalore, ²Head of Department, Department of Anesthesiology, Bangalore Baptist Hospital, Hebbal, Bellary Road, Bangalore

Abstract

Congenital diaphragmatic hernia (CDH) usually presents in the neonatal period with respiratory distress. The presentation in adults varies from asymptomatic to unexplained symptoms, which makes CDH difficult to diagnose. We report an anaesthetic management of CDH repair in an adult patient, who presented with abdominal pain. CDH was an incidental finding. The patient was planned for laproscopic CDH repair, keeping thoracotomy as alternative. Anaesthetic management was complicated by pulmonary hypoplasia on affected side, pulmonary hypertension and need of one lung ventilation. Postoperatively analgesia was also a challenge to prevent atelectasis.

Keywords – Congenital diaphragmatic hernia; pulmonary hypoplasia; thoracotomy.

Introduction

Congenital diaphragmatic hernia (CDH) usually presents immediately after birth with severe respiratory distress, which is life threatening. Its incidence is 1:2000 - 1:5000 live births with equal gender preference¹⁻⁴. In adults CDH presents with unexplained symptoms⁵ (Table 1) and based on computed tomography in 13,138 patients the incidence⁶ was found to be 0.17.

CDH develops due to failure of the posterolateral diaphragmatic foramina to fuse properly in eighth to tenth week of foetal life. Left-sided herniation is common, as right hemidiaphragm develops earlier and the liver prevents hollow viscus from herniation⁷. For anesthesiologists CDH repair is a challenge because of high risk of aspiration, need for lung isolation to prevent over distension of lungs and facilitate good view to surgeons, a ventilation strategy and pharmacological treatment to prevent pulmonary hypertension in hypoplastic lung and post operative analgesia to prevent

any further respiratory compromise.

Case Presentation

A 26 year old male patient (height 160cm, weight 56kg, BMI 21.8 kg/m²) presented to our emergency department with complaints of left sided upper abdominal pain and vomiting for the last one week. He had similar complaints in past also, which were managed conservatively outside and not diagnosed as CDH. There was no symptom suggestive of respiratory compromise. He had no history of any major trauma and other co morbidities. He was a cook by profession, with limited physical activity and effort tolerance was 3 - 4 METS.

On examination heart rate was 92/minute, blood pressure 120/80mm hg, respiratory rate 18/minute with no use of accessory muscle and room air saturation was 92 -93Mallampatti grading was class 1. On auscultation normal vesicular breath sound were heard on right side and decreased breath sound on left side. His systemic examination showed no other abnormalities.

Complete blood count, renal profile, serum sodium, serum potassium and ECG were normal. Arterial blood gas analysis showed pH 7.4, CO₂ 24, HCO₃ 14.6, P O₂ 77, BE -8.6, S O₂ 95.6. Chest radiography revealed absent lung marking on left side, right sided mediastinal

Correspondence author:

Dr Smriti Sinha

E mail id- smritii576@gmail.com

Ph No: (080)22024700, Fax: 23437970,

www.bangalorebaptisthospital.org

shift, nasogastric tube coiling back to left hemithorax, and blunting of margin of left dome of diaphragm (Fig 1). CT revealed stomach, small bowel and spleen as contents of the diaphragmatic hernia. Laparoscopic surgical repair was planned keeping thoracotomy as an alternative in case of very large defect.

Comprehensive contingency plans were developed preoperatively including thoracic epidural to manage postoperative pain in case of thoracotomy and double lumen endotracheal tube (DLT) to secure airway and facilitate lung isolation. A written and informed anesthetic consent was taken with explanation focused on postoperative ICU admission and ventilation. For aspiration prophylaxis fasting of 6 hours for solid and 2 hours for liquid and premedication with injection (inj) Ranitidine 50mg intravenously (IV) and inj Metoclopramide 10mg IV one hour before surgery was given.

The right radial artery cannulation (20G, Vasofix, BBraun) , one wide bore (Vasofix, 16G, BBraun) intravenous cannulation and right basilic central line (Cavafix 375, 14G, BBraun) were secured. Thoracic epidural (Perifix, 18G, B Braun) secured in T8 – T9 space. Monitoring included standard ASA monitors, temperature, invasive pressure monitoring and anesthetic agent analyzer.

Rapid sequence induction (RSI) was planned to avoid bag and mask ventilation and further airway compromise. After preoxygenation with 100% oxygen for three minutes, induction done with inj Fentanyl 100 microgm IV, Propofol 100mg IV and Succinylcholine 75mg IV. Left sided double lumen endotracheal tube size (Mallinckrodt, 37 F Broncho cath) was used to secure airway and position confirmed by fiberoptic bronchoscope. Anesthesia was maintained with oxygen, air, Isoflurane and inj Vecuronium. The epidural was activated with 0.5% Bupivacaine infusion at rate of 5ml/hr, half an hour after induction. Inj Morphine 6mg IV and inj Paracetamol 1gm IV as multimodal analgesia. Surgery was done in a reverse trendelenberg position with CO2 insufflation, which was filling thoracic cavity also. We planned for volume controlled ventilation with low tidal volume (5ml/kg) and high respiratory rate (20/min) with PEEP (5mm hg), keeping airway pressures within normal limits. The diaphragmatic defect was too large to close with laparoscopic approach, so thoracotomy was required for primary closure. One lung ventilation

started to right lung and the patient maintained saturation of 92-94% intraoperatively on 0.5 Fi O₂. The procedure took 5 hrs and intraoperative course was uneventful. After mesh repair, 0.1% Bupivacaine with 1 microgm/ml Fentanyl started epidurally at rate of 5ml/hr. The thoracic cavity was drained by a chest tube. Inj Ondansetron 6mg IV given towards end of surgery, muscle relaxation was reversed by inj Neostigmine 2.5mg IV and inj Glycopyrrolate 0.5mg and patient extubated. Patient was pain free with stable vitals and maintaining saturation. Postoperatively chest X ray revealed left sided chest expansion, and patient maintained normal vitals. The chest tube was removed on postoperative day 3 and discharged on postoperative day 7.

Table 1 – Misleading symptoms in order of frequency⁶

| Abdominal | Intrathoracic |
|-------------------------|------------------------|
| Cholecystitis | Cardiac disease |
| Cholelithiasis | Emphysema |
| Gastric ulcer | Congenital cystic lung |
| Duodenal ulcer | Pleural effusion |
| Secondary anaemia | Tuberculosis |
| Stricture of esophagus | Carcinoma cardia |
| Appendicitis | |
| Intestinal obstructions | |

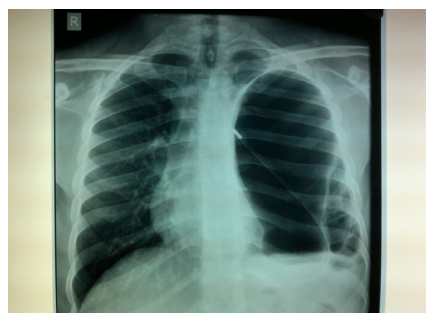

Fig 1: Chest radiography revealing absent lung marking on left side, right sided mediastinal shift, nasogastric tube coiling back to left hemithorax, and blunting of left dome of diaphragm.

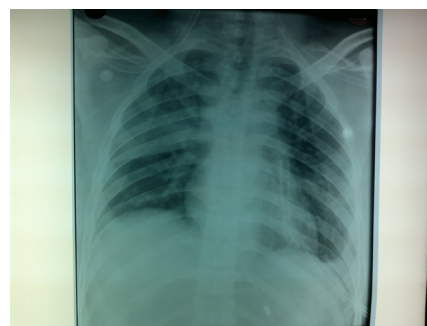


Figure2: Chest X ray showing post operatively expansion of left lung

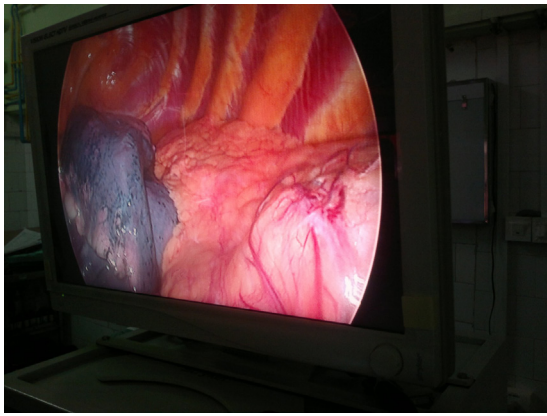


Fig 3 – Laparoscopic view showing hypoplastic lung on affected side after reduction of content.

Conclusion

The diagnosis of CDH in adult is not easy and needs high degree of suspicion. Unlike infants who presents with respiratory compromise, adults presents with slight respiratory and digestive system complaints⁸. Consequently many patients remain undiagnosed or just treated symptomatically. Chest X rays are most easily available imaging study which can detect CDH. Once diagnosis is made surgery should be performed as soon as possible to prevent worsening of the condition and complication. Minimal invasive surgical approaches are better to reduce the postoperative mortality and morbidity⁹.

These patients are at risk of aspiration so proper aspiration prophylaxis and RSI should be planned to avoid bag and mask ventilation and further respiratory compromise. One lung ventilation should be planned for these cases for optimizing surgical conditions. The presence of a hypoplastic lung and pulmonary hypertension should be kept in mind because of late presentation and ideally 2 D ECHO should be done. We accepted the patient on emergency basis so 2 D ECHO could not be done, but keeping possibility of pulmonary hypertension in mind, hypoxia, hypercarbia, acidosis and nitrous oxide were avoided. Pain should be managed well by epidural analgesia or patient controlled analgesia.

Overall anesthetic principles remain same in both infants and adults, with more careful attitude.

Source of Funding – Nil

Conflict of Interest – None

Ethical Clearance - It was obtained from institutional ethics committee, Bangalore Baptist Hospital.

References

1. Merin RG. Congenital diaphragmatic hernia from the anesthesiologist viewpoint. *Anesth Analg* 1966; 45: 44-52
2. Durham TM, Green JG, Hodges ED, Nique TA. Congenital diaphragmatic hernia: implications for nitrous oxide use in dentistry. *Spec Care Dentist* 1993; 13: 107-9
3. Cullen MI, Klein MD, Philippart AI. Congenital diaphragmatic hernia. *Surg Clin North Am* 1985; 11: 1115-38
4. Williams R. Congenital diaphragmatic hernia: a review. *Heart Lung* 1982; 11: 532-40
5. Kirkland et al; Congenital posterolateral diaphragmatic hernia in adult; *July 1959*; 47:201:16-22.
6. Mullins ME, Stein J, Saini SS, Mueller PR: Prevalence of incidental Bochdalek's hernia in a large adult population. *AJR Am J Roentgenol* 2001, 177:363-366.
7. Robinson PD, Fitzgerald DA. Congenital diaphragmatic hernia. *Paediatr Respir Rev* 2007;8:323-35.
8. Zhou et al; Giant congenital diaphragmatic hernia in adult; *Journal of cardiothoracic surgery*; 2014;9:31.
9. Vijfhuize et al; Minimal Access Surgery for Repair of Congenital Diaphragmatic Hernia: Is it Advantageous?—An Open Review; *European journal of pediatric surgery*; 2013; 22; 364-373.